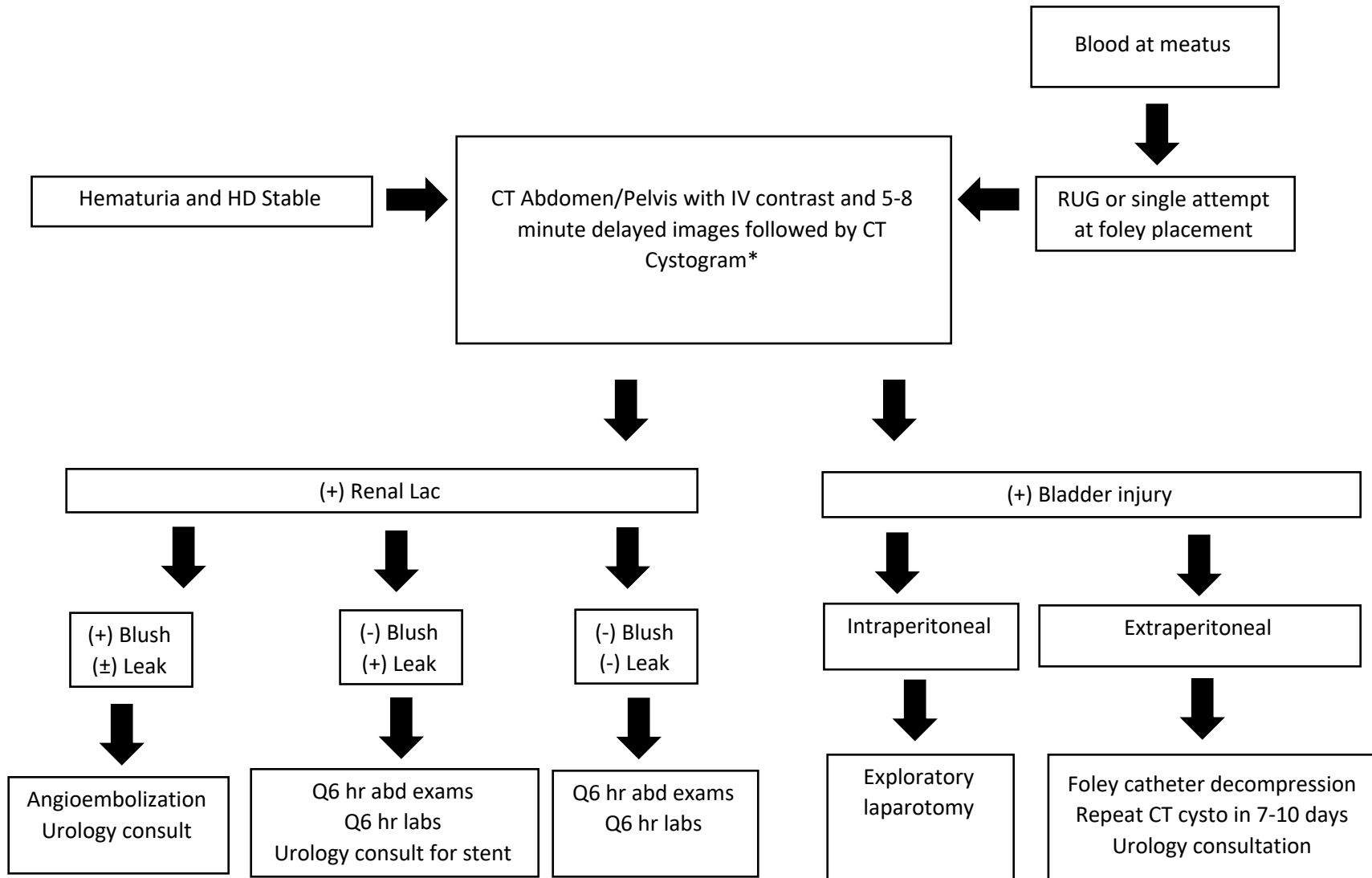


Genitourinary Trauma (Kidney, Ureter, Bladder)



*CT Cystogram: Place foley (if blood at meatus a single careful attempt or RUG first) and clamp. Instill 250 mL contrast into the bladder. Don't forget to unclamp the foley when study is complete.