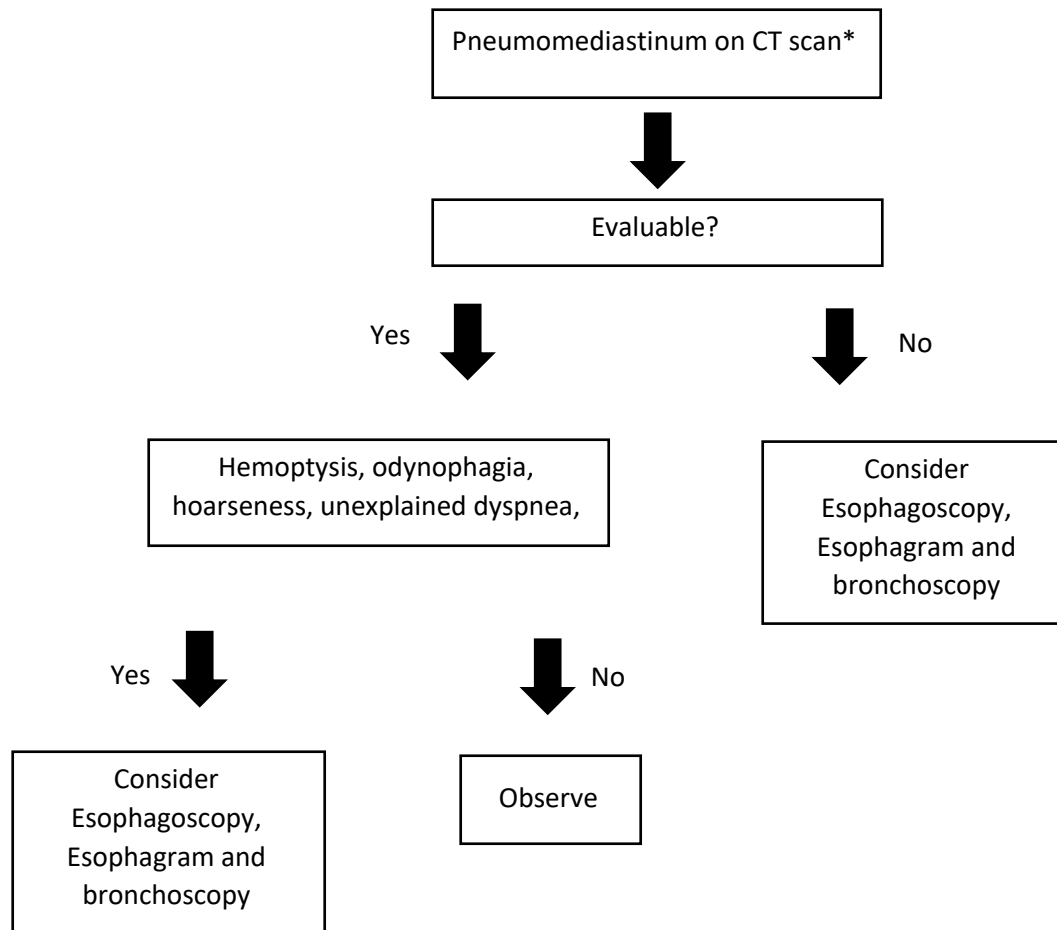


Pneumomediastinum Evaluation and Management



*CT findings of posterior pneumomediastinum, air in all mediastinal compartments, and concurrent hemothorax are associated with increased mortality (up to 40%).